

DEMODEX SP. (ACARI, DEMODECIDAE) AND DEMODECOSIS IN DOGS: CHARACTERISTICS, SYMPTOMS, OCCURRENCE

JOANNA N. IZDEBSKA

Laboratory of Parasitology and General Zoology, Department of Invertebrate Zoology,
University of Gdansk, 81-378 Gdynia, Poland
biojni@ug.edu.pl

Received for publication February 18, 2010

Abstract

The occurrence of skin mites from the family *Demodecidae* was investigated in dogs in Poland, from the Gdańsk region. Samples of healthy skin from 39 dogs and samples of diseased skin from two dogs were examined. Three species of hair follicle mite were found, among them *Demodex cornei* and *D. injai* for the first time in Poland. *D. canis* and *D. cornei* were present on dog skin asymptotically and usually synhospitalically – the former species on 42% and the latter on 7% of the skin samples. *D. injai* was found exclusively in correlation with the occurrence of symptoms of demodecosis in two mongrel dogs. The three species of hair follicle mite specific to dogs not only differed morphologically but were also found on different areas of the hosts' skin. The differentiation in structure, biology, and microhabitats of these mites may be associated with the occurrence of forms of demodecosis with different symptoms and courses in dogs.

Key words: dog, *Demodecidae*, demodecosis, symptoms, pathology, Poland.

Dog hair follicle mites are some of the longest known and best researched representatives of the *Demodecidae* family. Nevertheless, despite a whole range of studies and reports from all around the world on canine demodecosis (demodicosis), its symptoms, and methods of treatment, knowledge of its aetiology is far from complete. For more than a hundred years all cases of canine demodecosis have been laid at the door of one species, *Demodex canis*. Yet there is no doubt that some of these cases may have been due to infection by other hair follicle mites, unidentified at the time, especially as the diversity of symptoms and the different courses of demodecosis, as well as the difficulties in treating it, suggest that this may be parasitosis with a very complex aetiology. *D. canis*, known since the 19th century, has been accurately described in great detail by numerous authors, e.g. Leydig (24), Canestrini and Kramer (4), Hirst (15), French (11), and Nutting and Desch (29), which should facilitate identification. However, it was not until recently that a second dog hair follicle mite – *Demodex injai* (8) – was identified; in addition, there have been reports on infection by a so-called short form (6, 7, 25, 36), which has also been recognised as a separate species – *Demodex cornei* (25) – later described in detail on the basis of examination under a scanning microscope (38).

Demodex injai has so far been found in the USA, Australia, and Spain (8, 14, 27, 31, 34). On the other hand, *D. cornei*, or its corresponding “short forms” or “short-tailed forms”, has been found, always in the

correlation with the symptoms of demodecosis, in USA, England, Portugal, Greece, China, Japan, Venezuela, and Australia (1, 6, 7, 25, 30, 35, 38). It seems highly probable, however, that these recently described species came across earlier, but that the symptoms they caused were ascribed to *D. canis*.

D. injai has now been found in Poland, in two dogs with serious skin lesions. Asymptomatic infection by *D. cornei* has been found in dogs examined in recent years.

Material and Methods

The skin samples were taken from 41 dead dogs in the Gdańsk region between 2001 and 2008. The dogs were from 5 weeks to 12 years old, of different breeds and sexes; more than half were mongrels. 39 of these dogs, sent for examination from animal sanctuaries, did not exhibit symptoms of demodecosis; the other two dogs – both strays – had distinct skin lesions. The skin samples were taken from the head (eyelid, cheek, nose, ear, upper lip), fore and hind groins, limbs (the knee region), belly, and genital-anal regions. They were preserved in 70% ethanol solution, then analysed using the standard method of skin digestion (22). The digested samples were examined under a phase-contrast microscope. All the mites found were mounted in Faure's medium.

Table 1
Comparison of characteristic of *Demodex* spp. living on the domestic dogs
(body measurements were based on 30 parasites from each species)

Features	<i>Demodex canis</i>		<i>Demodex injai</i>		<i>Demodex cornei</i>	
	male	female	male	female	male	female
Body length (μm)	192 (165-217)	223 (205-265)	367 (309-411)	339 (282-396)	121 (93-135)	137 (125-165)
Body width (μm)	36 (33-40)	40 (35-43)	43 (40-47)	45 (41-48)	35 (33-40)	38 (35-40)
Ratio of length to width	5.3	5.6	8.5	7.5	3.5	3.6
Ratio of length opisthosoma to body length (%)	51	59	71	68	39	42
Habitat	hair follicles		sebaceous glands		epidermis	

Results

Three species of mite were found: *Demodex canis*, *D. cornei* and *D. injai* (Table 1), the latter two being recorded for the first time in Poland (Gdańsk locality) (19).

D. canis (Figs 1, 2) was found in the skin of 17 dogs (prevalence nearly 42%, mean intensity 11, range of intensity 1-312); its presence was asymptomatic, with the greatest intensities on the eyelids and upper lip. *D. injai* (Figs 1, 4) was found in the two dogs with distinct skin lesions (prevalence nearly 5%, mean intensity 188, range of intensity 155-221), whereas *D. cornei* (Figs 1, 3) was present in three dogs (prevalence above 7%, mean intensity 12, range of intensity 8-15). In one of these dogs, the infection by both species, *D. cornei* and *D. canis*, was synhospitalic.

Description of two cases of demodicosis caused by *Demodex injai*. *Demodex injai* was found in two dogs, in 2008 and 2009; both animals were examined *post mortem*. They exhibited skin lesions, and numerous specimens of *D. injai* (all developmental stages) were found in the examined skin samples. The lesions in both dogs – male mongrels aged 11 and 7 years, and weighing 5 and 9 kg respectively – were of varying intensity in different skin regions.

In the first dog the most serious lesions were on the head (particularly in the periorbital region, and on the forehead and ear lobes), the shoulders, limbs, belly and anal-genital region, and also at the basis of the tail. The lesions on the head and back were scabby, with large areas of skin peeling away; in places the skin was broken, and there were signs of alopecia. There were numerous pustules on the limbs and in the groins.

In the second dog, the lesions were particularly intensive on the head and outer surfaces of the limbs. The skin was reddened; the skin on the head had peeled in places, giving rise to patchy alopecia, and there were scabs on the limbs. The lesions in this dog were less intensive than in the first animal.

Numerous specimens of *D. injai* were digested from the samples of diseased skin from both dogs. Single specimens of these mites were also found in other skin regions, but symptoms of demodicosis were either mild or absent altogether.

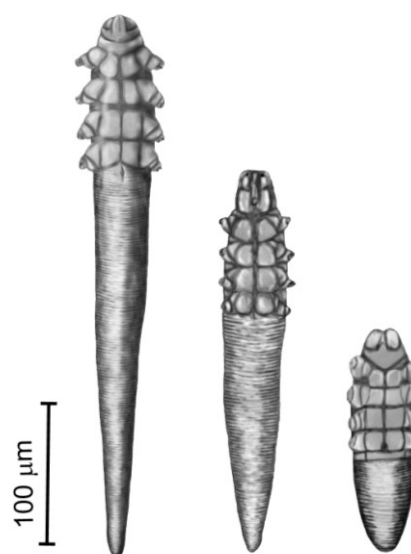


Fig. 1. *Demodex injai*, *D. canis*, *D. cornei* (females, ventral view).

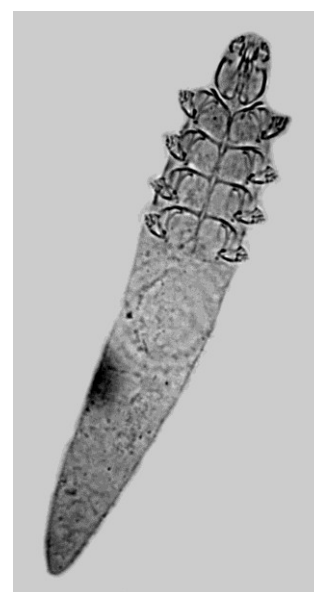

Fig. 2. *Demodex canis*.

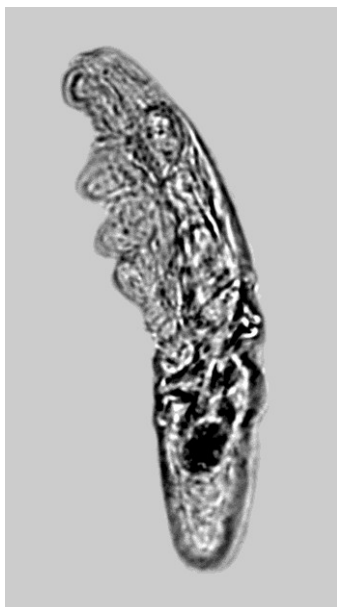

Fig. 3. *Demodex cornei*

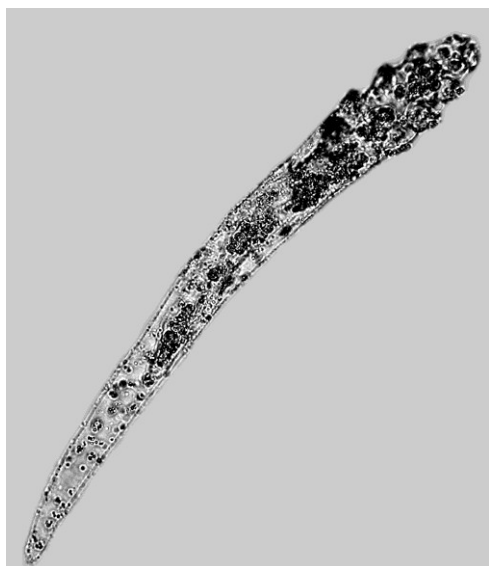


Fig. 4. *Demodex injai*.

Discussion

Canine demodecosis is one of the most common skin diseases in veterinary practice (26). The causative agents, the hair follicle mites, are typical canine parasites. Their prevalence in dog populations varies. According to studies carried out in Poland, it ranges from ca. 39% (33) to 85% (37), whereby infection is usually asymptomatic (e.g. 21, 33, 37). The symptoms of demodecosis usually appear when a high level of mite infection is correlated with diminished host resistance (13).

Canine demodecosis has been extensively described, beginning with the classic works of Canestrini and Kramer (4), Gmeiner (12), and Hirst (15). Later papers and communications focused on the development and course of the disease, its symptoms

and variants, histopathological changes, and methods of diagnosis and treatment (2, 5, 10, 23, 26, 32). In all these publications, however, the skin lesions caused by canine demodecosis were always attributed to *D. canis*. Descriptions of infections by the other two species of hair follicle mite have only appeared recently, for example, the earlier-mentioned data on the infection by *D. cornei* from Europe, Asia, and Australia (3, 6, 7, 35, 38) and by *D. injai* from the USA and Europe (8, 14, 31). Now it seems likely that in some of the earlier cases, the aetiological factor was not always correctly defined and the cause of the described infections could have been a different species, or also the synhospitalic infestation by two species.

Therefore, establishing the frequency of the occurrence of the three species of hair follicle mite in dog populations appears to be a matter of importance – analysis of asymptomatic infestations would provide the best picture of this. According to the present study, *D. canis* is the species with the greatest prevalence, while the other two species are far less common. These three mite species not only differ morphologically (see Figs 1, 2, 3 and 4, Table 1), they also colonise different habitats on the skin of dogs. *D. canis* inhabits primarily the hair follicles on the head – usually in the periorbital regions, and on the cheeks and upper lip. Only when the level of infection is high these mites are to be found in other skin regions; it is often the case that once follicles have degraded, the mites colonise other skin layers – they have even been found in the lymphatic and digestive systems. *D. cornei* has always been found in the horny layer of the epidermis (7), which is hardly surprising, since in the *Demodecidae*, the shape, dimensions, and proportions of the body are a strict adaptation to the microhabitat occupied (17, 20). In this case, the structure, small size, and proportions are similar to those of the mite species inhabiting similar locations in other mammals, e.g. *D. gatoi* in the cat and *D. criceti* in the Syrian hamster. In contrast, *D. injai* is associated with the sebaceous glands and their excretory ducts; its strongly elongated shape and body proportions resemble those of species colonising similar habitats in other hosts, e.g. *D. caballi* in the horse, *D. ghanensis* in cattle, and *D. bisonianus* in the European bison (9, 17, 18, 20).

Besides the well-known host specificity, this topical specificity appears to be a characteristic feature in the evolution of the *Demodecidae*, which have developed specific adaptations to life, feeding, reproduction, and transmission in different types of skin microhabitats on particular host species. Within particular host taxa, this has led to the speciation of synhospitalic hair follicle mites with different topographies and specific requirements vis-à-vis skin tissues. Analogous associations of synhospitalic species have been described in rats (four species), cattle (three species), and in horses, sheep, and cats (two species each) (16, 19, 20, 28).

It seems likely that the different species found in different locations on the skin, and therefore with diverse adaptive strategy, biology, reproductive cycles etc., may be the cause of infections taking different courses and giving rise to different sets of symptoms.

Therefore, when diagnosing canine demodicosis, it is important to identify correctly the species of hair follicle mite causing the disease.

References

- Alvarez L., Medina O.C., García M.E., García H.: First report of an unclassified *Demodex* mite causing demodicosis in a Venezuelan dog. *Ann Trop Med Parasitol* 2007, **101**, 529-532.
- Baker K.P.: Observations on demodectic mange in dogs. *J Small Anim Pract* 1968, **9**, 621-625.
- Bensignor E., Guaguere E., Prelaud P.: Demodicosis due to *Demodex injai* in dogs: eight cases. *Vet Dermatol* 2006, **17**, 356-357.
- Canestrini G., Kramer P.: *Demodicidae* und *Sarcoptidae*. Volume 7 in *Das Tierreich* Series. R. Friedländer und Sohn, Berlin, 1899, p. 193.
- Caswell J.L., Yager J.A., Ferrer L., Weir J.A.M.: Canine demodicosis: A re-examination of the histopathologic lesions and description of the immunophenotype of infiltrating cells. *Vet Dermatol* 1995, **6**, 9-19.
- Chen C.A.: Short-tailed demodectic mite and *Demodex canis* infestation in a Chihuahua dog. *Vet Dermatol* 1995, **6**, 227-229.
- Chesney C.J.: Short form of *Demodex* species mite in the dog: occurrence and measurements. *J Small Anim Pract* 1999, **40**, 58-61.
- Desch C.E., Hillier A.: *Demodex injai*: A new species of hair follicle mite (*Acari: Demodicidae*) from the domestic dog (*Canidae*). *J Med Entomol* 2003, **40**, 146-149.
- Desch C.E., Nutting W.B.: Redescription of *Demodex caballi* (= *D. folliculorum* var. *equi* Railliet, 1895) from the horse, *Equus caballus*. *Acarologia* 1978, **20**, 235-240.
- Folz S.D., Geng S., Nowakowski L.H., Conklin R.D.: Evaluation of a new treatment for canine scabies and demodicosis. *J Vet Pharmacol Ther* 1978, **1**, 199-204.
- French F.E.: Two larval stadia of *Demodex canis* Leydig (*Acarina: Trombidiformes*). *Acarologia* 1953, **5**, 34-38.
- Gmeiner F.: *Demodex folliculorum* des Menschen und der Tiere. *Arch Dermatol Syphilol* 1908, **92**, 25-95.
- Healey M.C., Gaafar S.M.: Immunodeficiency in canine demodectic mange. I. Experimental production of lesions using antilymphocyte serum. *Vet Parasitol* 1977, **3**, 121-131.
- Hillier A., Desch C.E.: A new species of *Demodex* mite in the dog: a case report. Annual Members' Meeting of the American Academy of Veterinary Dermatology and the American College of Veterinary Dermatology Nashville, Tennessee, 1997, pp. 118-119.
- Hirst S.: Studies on *Acari*. No. 1. The Genus *Demodex*, Owen. British Museum (Natural History), London, 1919, p. 44.
- Izdebska J.N.: *Demodex* spp. (*Acari: Demodicidae*) in brown rat (*Rodentia: Muridae*) in Poland. *Wiad Parazytol* 2004, **50**, 333-335.
- Izdebska J.N.: Adaptation to parasitism in skin mites from the *Demodicidae* family (*Acari, Prostigmata*). In: *Arthropods. Epidemiological importance*. Edited by A. Buczek, and C. Błaszak, Koliber, Lublin, 2006, pp. 31-36.
- Izdebska J.N.: Skin mites (*Acari: Demodicidae, Psoroptidae, Sarcoptidae*) in the European bison, *Bison bonasus*. *Biol Lett* 2006, **43**, 169-174.
- Izdebska J.N.: Nużeńcowate (*Demodicidae*). In: *Fauna Polski - charakterystyka i wykaz gatunków*. Edited by W. Bogdanowicz, E. Chudzińska, I. Pilipuk, and E. Skibińska, Muzeum i Instytut Zoologii PAN, Warszawa, 2008, pp. 128-130, 200-201.
- Izdebska J.N.: Selected aspects of adaptations to the parasitism of hair follicle mites (*Acari, Demodicidae*) from hoofed mammals. *Eur Bison Conserv Newsl* 2009, **2**, 80-88.
- Izdebska J.N., Kadulski S., Fryderyk S.: Dynamika infestacji pasożytów zewnętrznych *Canis familiaris* i *Felis catus* (*Carnivora, Mammalia*) w rejonie Trójmiasta. In: *Stawonogi pasożyty i nosiciele*. Edited by A. Buczek and C. Błaszak, KGM, Lublin, Poland, 2001, pp. 93-98.
- Kadulski S., Izdebska J.N.: Methods used in studies of parasitic arthropods in mammals. In: *Arthropods. Epidemiological importance*. Edited by A. Buczek and C. Błaszak, Koliber, Lublin, Poland, 2006, pp. 113-118.
- Lemarié S.L., Hosgood G., Foil C.S.: A retrospective study of juvenile- and adult-onset generalized demodicosis in dogs (1986-91). *Vet Dermatol* 1996, **7**, 3-10.
- Leydig F.: Ueber Haarsackmilben und Krantzmilben. *Arch Natur Berlin*, 1859, **1**, 338-354.
- Mason K. V.: A new species of *Demodex* mite with *D. canis* causing canine demodicosis; a case report. Annual Members' Meeting of the American Academy of Veterinary Dermatology and the American College of Veterinary Dermatology San Diego, 1993, p. 92.
- Mueller R.S.: Treatment protocols for demodicosis: an evidence-based review. *Vet Dermatol* 2004, **15**, 75-89.
- Mueller R.S., Bettenany S.V.: An unusual presentation of canine demodicosis caused by a long-bodied *Demodex* mite in a Lakeland Terrier. *Austr Vet Pract* 1999, **29**, 128-130.
- Nutting W.B.: Hair follicle mites (*Demodex* spp.) of medical and veterinary concern. *Cornell Vet* 1976, **66**, 214-231.
- Nutting W.B., Desch C. E.: *Demodex canis* redescription and reevaluation. *Cornell Vet* 1978, **68**, 139-149.
- Oliveira A., Leitão J.P., Santos Grácio A.J., da Fonseca I.P.: Formas curtas de *Demodex* no cão – primeira descrição em Portugal. *Rev Port Cien Vet* 2007, **102**, 249-252.
- Ordeix L., Bardagi M., Scarampella F., Ferrer L., Fondati A.: *Demodex injai* infestation and dorsal greasy skin and hair in eight wirehaired fox terrier dogs. *Vet Dermatol* 2009, **20**, 267-272.
- Paradis M., Pagé N.: Topical (pour-on) ivermectin in the treatment of chronic generalized demodicosis in dogs. *Vet Dermatol* 1998, **9**, 55-59.
- Piotrowski F., Milko K.: Asymptomatic demodicosis in dogs. *Medycyna Wet* 1975, **31**, 466-469.
- Robson D.C., Burton G.G., Bassett R., Shipstone M., Mueller R.S.: Eight cases of demodicosis caused by a long-bodied *Demodex* species (1997-2002). *Aust Vet Pract* 2003, **33**, 64-72.
- Saridomichelakis M., Koutinas A., Papadogiannakis E., Papazachariadou M., Liapi M., Trakas D.: Adult-onset demodicosis in two dogs due to *Demodex canis* and a short-tailed demodectic mite. *J Small Anim Pract* 1999, **40**, 529-532.
- Scarff D.: Morphological differences in *Demodex* spp. Proceedings of the fifth Annual Congress of the European Society of Veterinary Dermatology, London, 1988, p. 23.
- Stankiewicz W., Augustynowicz L., Floriańczyk R., Janicka M., Malinowski W., Pawłowski K.: Trials of treatment of dogs with demodicosis. *Medycyna Wet* 1970, **26**, 13-15.
- Tamura Y., Kawamura Y., Inoue I., Ishino S.: Scanning electron microscopy description of a new species of *Demodex canis* spp. *Vet Dermatol* 2001, **12**, 275-278.